

## **Section 8.4: Horse Bone Report– Caroline Wilby**

**Horse Bone Report  
Parramatta Children's Court Site  
cnr George & O'Connell Streets, Parramatta**

**Caroline Wilby**

**for  
Casey & Lowe Pty Ltd**

**September 2005**

**LOCATION –**

22 horse elements within the PCC assemblage;

- 15 elements from Lot 103, Area F, Context 4110;
- 4 elements from Lot 103, Area F, Context 4104, and;
- 3 elements from Lot 103, Area F, Context 4102

**BODY PARTS –**

The majority of horse elements identified represent anatomical extremities:

- *Metacarpal and carpal* – lower fore limb;
- *Astragalus, calcaneus, tarsals & metatarsals* – hock joint and lower hind limb;
- *Phalanges* – digital bones (fore and / or hind limbs).

However, elements of the upper hind limbs are also present:

- 2 *femur* fragments, and;
- 5 *tibia* fragments.

The number and portions of elements identified allows an MNI calculation of one individual. It is likely that all elements identified are from the same horse.

**AGING –**

Based on epiphysial fusion on the long bones of the identified horse in conjunction with the generally accepted age charts for horses, the identified individual must be at least 3.5 years old.

Ages of epiphysial fusion in *Equus*:

<b>Femur</b>		<b>Tibia</b>	
<i>Proximal</i>	<i>Distal</i>	<i>Proximal</i>	<i>Distal</i>
3-3.5	3.5	3.5	2

Reference: Schmidt. E. (1972) *Atlas of Animal Bones for Prehistorians, Archaeologists and Quaternary Geologists*. Elsevier Publishing, Amsterdam.

**BUTCHERY –**

Evidence of butchery is identified on two horse elements (refer to Figures 1- 5);

- 1 left *Metatarsal III* (cut or chop marks) and;
- 1 right *astragalus* (saw marks).

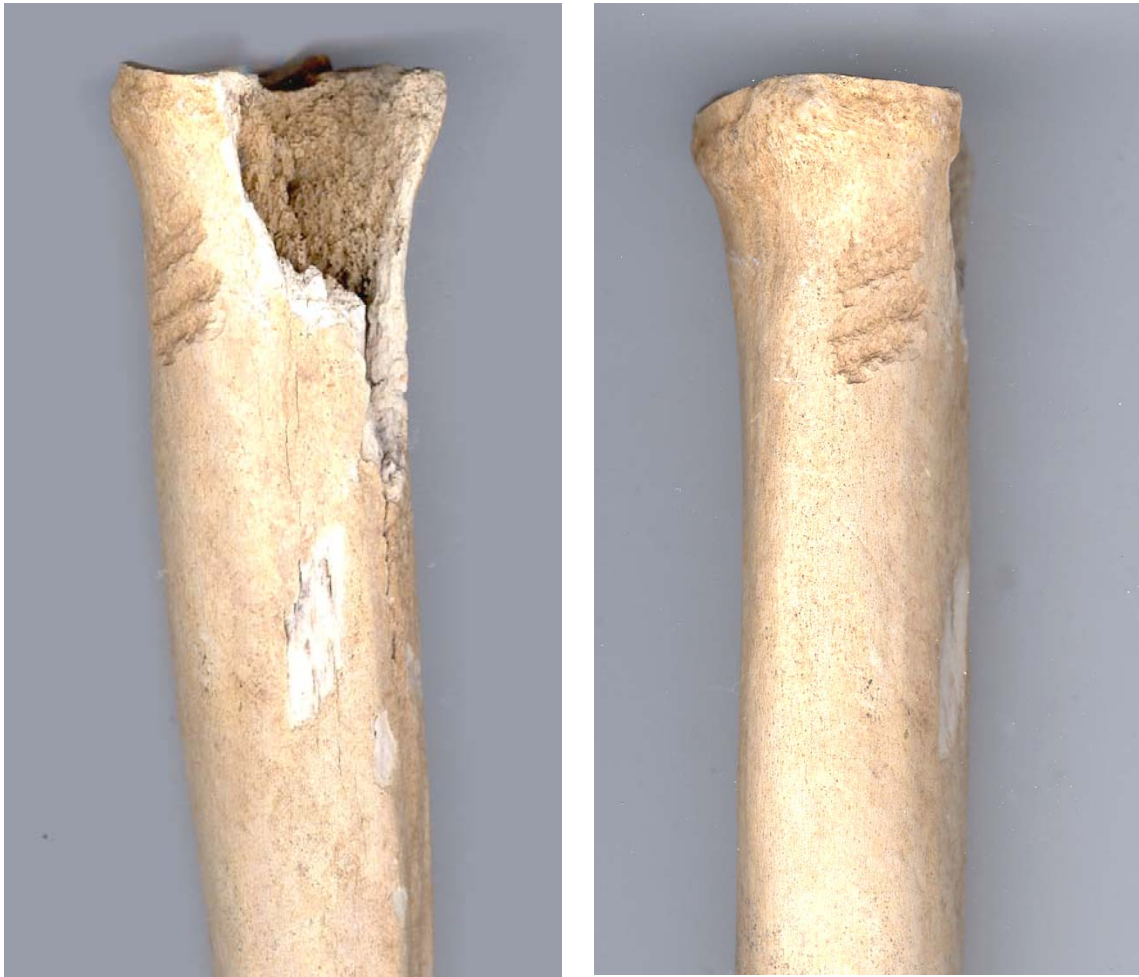
Butchery marks generally result from three activities: skinning, disarticulation and filleting. Skinning cut marks are found around the shaft of lower legs and phalanges and along the lower margins of the mandible or on the skull. Disarticulation cut marks occur on the edges or articular surfaces of the ends of long bones and on the surfaces of vertebrae or pelvic parts. Filleting cut marks generally parallel the long axis of the bone.

Under a very basic analysis, it may be suggested that the marks identified on the MTIII conform to skinning cut marks. The mark identified on the astragalus are very unusual – being located on an interior surface of the hock joint (refer to Figure 5). The cause or purpose of this mark is impossible to accurately identify.

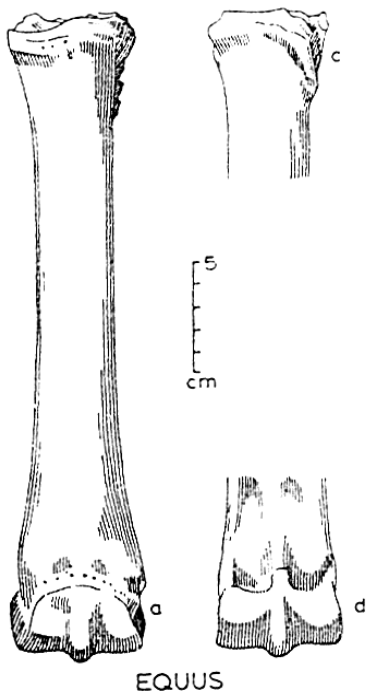
These marks provide evidence of some form of utilisation of the horse after its death – possibly evidence of the use of horse hides, or the consumption of horse meat by humans or pets (dogs). However, due to the very small sample size (1 horse, 2 cut marks), this assemblage does not provide conclusive evidence of any of the above activities and it is unlikely that any such activities were the primary reason for keeping horses on or near the site.

ID	Lot	Area	Context	Box	Species	Element	Orient	Portion	%	Aging	Butchery
1	103	F	4110	1	Horse	Femur	Right	Distal	80	Fused	
16	103	F	4110	1	Horse	Tibia	Left & Right	Mid	50		Left joins with left prox portion ID 493
17	103	F	4110	1	Horse	Metacarpal III	Right	Complete	100		
104	103	F	4104	6	Horse	1st Phalange	Left	Complete	100		
105	103	F	4104	6	Horse	Calcaneus	Right	Complete	100		
106	103	F	4104	6	Horse	Metatarsal III	Left & Right	Mid	90		Chop marks on proximal of left MT - mediolateral, x 3, surficial only
140	103	F	4102	4	Horse	2nd Phalange	Left & Right	Complete	100		
141	103	F	4102	4	Horse	1st Phalange	Right	Mid	90		
167	103	F	4110 sp 1	4	Horse	Tarsal III	Left	Complete	100		
487	103	F	4110	5	Horse	Astragalus	Right	Complete	100		Saw marks on distal articular surface, axial, surficial
488	103	F	4110	5	Horse	1st Phalange	Right	Complete	100		
489	103	F	4110	5	Horse	2nd Phalange	Left	Complete	100		
490	103	F	4110	5	Horse	Tarsal	N	Complete	100		
491	103	F	4110	5	Horse	Carpal	N	Complete	100		
492	103	F	4110	5	Horse	Femur	N	Proximal	10	Fused	
493	103	F	4110	5	Horse	Tibia	Left & Right	Proximal	20	Fused	Left joins with left mid portion ID 106
494	103	F	4110	5	Horse	Tibia	Right	Distal	10	Fused	
495	103	F	4110	5	Horse	Astragalus	Left	Complete	100		

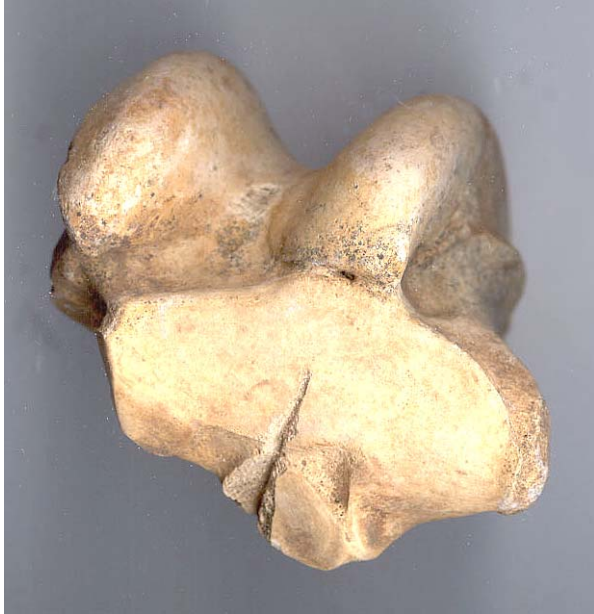**List of Horse elements found within the well backfill, Lot 103**



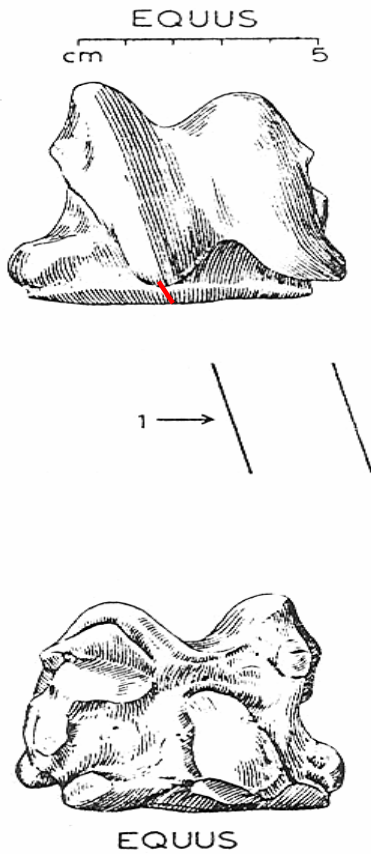
**Figure 1:** Cut marks identified on left metatarsal III



**Figure 2:** Schematic illustration of cut marks identified on left metatarsal III (base ref: Schmidt. E. (1972) *Atlas of Animal Bones for Prehistorians, Archaeologists and Quaternary Geologists*. Elsevier Publishing, Amsterdam.



**Figure 3:** Cut mark identified on right astragalus



**Figure 4:** Schematic illustration of location of cut mark identified on right astragalus (base ref: Schmidt. E. (1972) *Atlas of Animal Bones for Prehistorians, Archaeologists and Quaternary Geologists*. Elsevier Publishing, Amsterdam.

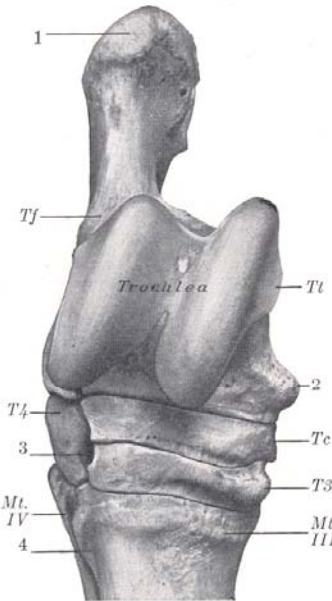


FIG. 102.—RIGHT TARSUS AND PROXIMAL PART OF METATARSUS OF HORSE; ANTERIOR OR DORSAL VIEW.  
Tt, Tibial tarsal bone; Tf, fibular tarsal; Tc, central tarsal; T3, third tarsal; T4, fourth tarsal; 1, tuber calcis; 2, distal tuberosity of tibial tarsal; 3, vascular canal; 4, groove for great metatarsal artery; Mt. III, IV, metatarsal bones.

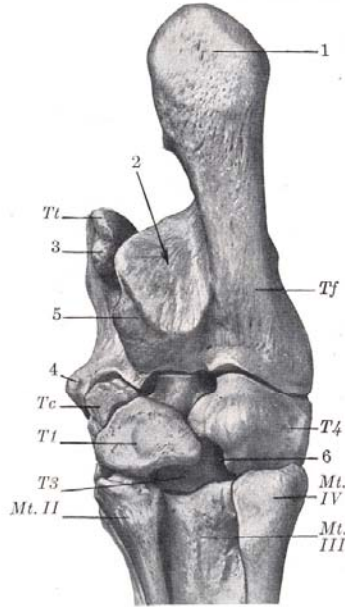


FIG. 103.—RIGHT TARSUS AND PROXIMAL PART OF METATARSUS OF HORSE; POSTERIOR OR PLANTAR VIEW.  
Tt, Tibial tarsal bone; Tf, fibular tarsal (body); Tc, central tarsal; T1, first tarsal (fused with second); T3, third tarsal; T4, fourth tarsal; 1, tuber calcis; 2, tarsal groove for deep flexor tendon; 3, proximal tuberosity of tibial tarsal; 4, distal tuberosity of same; 5, sustentaculum; 6, vascular canal; Mt. II, III, IV, metatarsal bones.

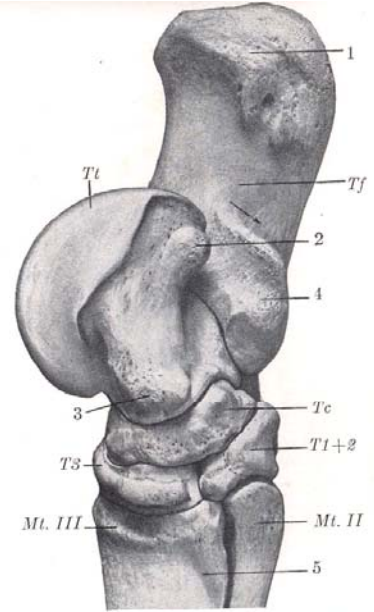


FIG. 104.—RIGHT TARSUS AND PROXIMAL PART OF METATARSUS OF HORSE; MEDIAL VIEW.  
Tt, Tibial tarsal (trochlea); Tf, fibular tarsal; Tc, central tarsal; T1+2, fused first and second tarsals (dotted line indicates division between two elements); T3, third tarsal; 1, tuber calcis; 2, 3, proximal and distal tuberosities of tibial tarsal; 4, sustentaculum; 5, groove for great metatarsal vein; Mt. II, III, IV, metatarsal bones. Arrow indicates course of flexor tendon in tarsal groove.

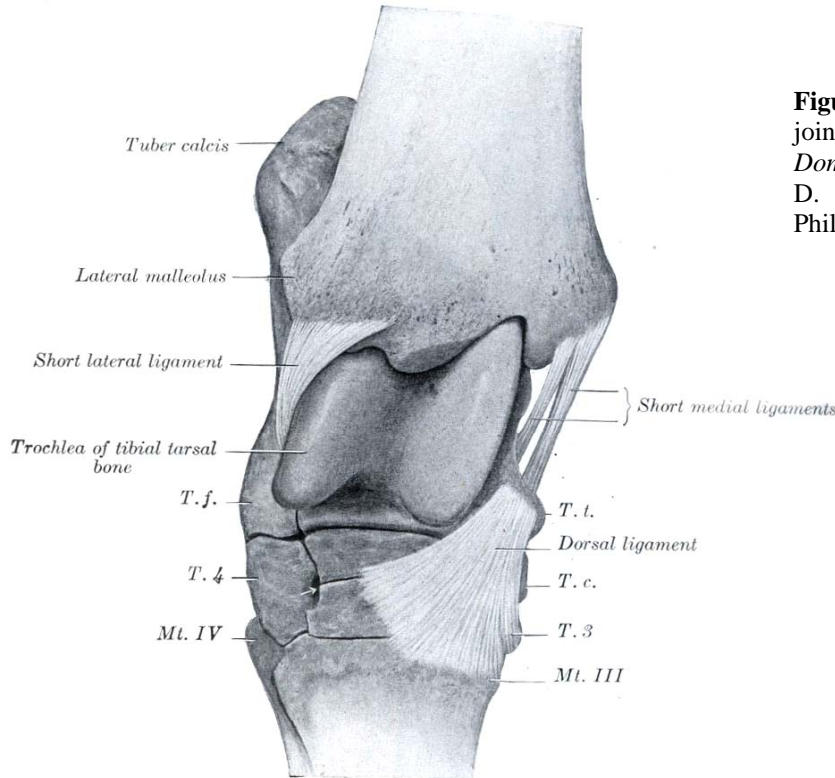


FIG. 254.—RIGHT HOCK JOINT OF HORSE. VIEWED FROM THE FRONT AND SLIGHTLY Laterally AFTER REMOVAL OF JOINT CAPSULE AND LONG COLLATERAL LIGAMENTS.  
T. t., Tibial tarsal bone (distal tuberosity); T. c., central tarsal bone; T. 3, ridge of third tarsal bone; T. f., fibular tarsal bone (distal end); T. 4, fourth tarsal bone; Mt. III, Mt. IV, metatarsal bones. Arrow points to vascular canal.

**Figure 5:** Illustration of astragalus within hock joint (Sisson, S. (1941) *The Anatomy of the Domestic Animals*. Third edition, revised by J. D. Grossman. W. B. Saunders Company, Philadelphia & London).